

Functional Outcome of Bilateral Total Hip Arthroplasty by Posterolateral Approach: A Prospective Study in Indian Population

Choudhari P, Jain N, Deshpande M, Chauhan R

Study performed at Department of Orthopaedics, Sri Aurobindo Institute of Medical College & Post Graduate Institute, Indore (M.P.)

Abstract

Background: Total hip arthroplasty (THA) is the most widely accepted surgical procedure for the treatment of Avascular necrosis of femoral head, with favourable clinical outcomes having been reported in various studies. Most patients that undergo THA suffer from primary osteoarthritis. The posterolateral (Moore's) approach to hip permits easy access with fewer tissue dissection and blood loss while raising the risk of neural injury and postoperative dislocation of the prosthesis.

Material and Methods: This longitudinal study was conducted on 50 arthritic hips (25 patient) operated by a single surgeon with Bilateral THA via posterolateral approach (Southern Moore's approach). All patients with bilateral osteoarthritis of hip secondary to avascular necrosis of hip (grade III or IV) more than 18 years of age, patients with normal septic profile and patients who were willing to undergo total hip arthroplasty according to our protocol were included in the study. The patients were followed up at the end of 6 weeks, 3 months and six months postoperatively after bilateral THA.

Results: Among 25 patients in this study, 20 patients (80%) were males and 5 patients (20%) were females. All the patients were between 18 to 60 years of age. The most common etiology for AVN was idiopathic in 11 patients (44%) followed by Steroid abuse in 8 patients (32%). The most common complication encountered in our study was Limb length discrepancy (LLD) in 3 patients (12%) followed by Posterior Dislocation of hip in 2 patients (8%). The mean pre op HHS was 28.22 and 26.73 for right and left hip which improved significantly post operatively with HHS of 82.36 after 6 months post operatively which suggest excellent improvement in clinical outcome.

Conclusion: Uncemented bilateral THA can be used in patients with excellent to good functional outcome at midterm follow-up, high satisfaction rate and lower rate of complications. Longer follow-up and multi-centric studies with larger sample size are necessary to establish confirmatory results.

Key Words: Arthroplasty, Hip, Bilateral, Avascular necrosis

Address of correspondence:

Dr. Pradeep Choudhari
7/3/3, Ahilaya Mata Colony, Near
Charak Hospital, Rani Sati Gate,
Indore-452003
Email – pchoudhari@rediffmail.com

How to cite this article:

Choudhari P, Jain N, Deshpande M, Chauhan R. Functional Outcome Of Bilateral Total Hip Arthroplasty by Posterolateral Approach: A Prospective Study in Indian Population. Ortho J MPC. 2021;27(1):37-41



Introduction

Total hip arthroplasty (THA) is the most widely accepted surgical management for the treatment of avascular necrosis of femoral head, with favourable clinical outcomes reported in numerous studies [1-5]. THA is also considered as most effective and definitive treatment for osteoarthritis and

other hip pathologies, such as rheumatoid arthritis, ankylosing spondylitis and osteonecrosis [6,7].

Approximately 20% of all patients who underwent THA will need surgery of the contralateral hip, at some time [8]. Studies suggest that since THA is most commonly done for primary osteoarthritis, which is

usually a bilaterally involving hip pathology, and so patients, with unilateral THA could need a contralateral THA within 10 years [9,10]. Literature lacks in mid-term outcomes of bilateral THA in the Indian population.

Many surgical approaches to the hip are described, each with its distinctive advantages and disadvantages [11]. While some studies have found statistical associations between approach and outcome, most consider the individual surgeon's comfort and proficiency with an approach as most important [12]. The posterolateral (Moore's) approach which is most commonly used approach, permits quick access to hip joint with lesser tissue dissection and blood loss, but raising the risk of neurovascular injury and postoperative dislocation of the prosthesis [13-18]. In view of lack of literature on outcomes of bilateral THA, we evaluated the outcome of bilateral THA operated by posterolateral approach.

Material and Method

This longitudinal study was conducted from January 2018 to Jan 2020 in Orthopaedic department of our tertiary care centre in 25 patients with 50 arthritic hips who were operated by a single surgeon (1st Author) with bilateral THA via posterolateral approach (Southern Moore). Institutional ethical committee clearance and informed written consent was obtained before the study.

All patients of age more than 18 years with bilateral osteoarthritis or avascular necrosis of hip with grade III or IV were included in the study. Patients age less than 18 years, unilateral hip pathology, unfit for surgery or ankylosed hip were excluded from the study. In all the cases bilateral THA was performed, which was done as staged surgery and the second hip was replaced within 2 months of first THA.

All the patients were subjected to thorough history, clinical examination and investigations which include routine pre-operative profile, ESR and CRP. Standard pelvic roentgenogram true AP view with both hips including the upper third of femur, 15 degrees of internal rotation AP view and lateral X-rays of the hip were taken to estimate the anatomic relationship of the femur and pelvis, so that

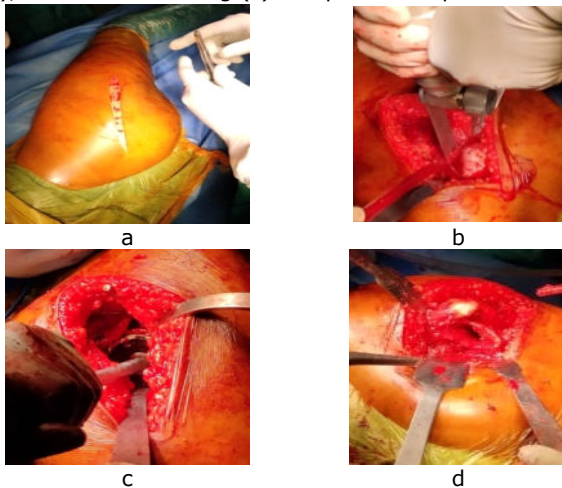
accurate restoration of combined anatomy and biomechanics of hip can be achieved. Aspirin, anticoagulants and other anti-inflammatory drugs, if patient was on, were stopped 7 days before the surgery. Any occult infections like skin lesion, dental caries, and urinary tract infections were recognised and treated preoperatively.

All patients were operated in lateral position following sterile techniques under spinal anaesthesia via southern Moore's approach. A 15 cm incision centring over the greater trochanter was given, extending from the posterior border of greater trochanter curving posteriorly along the fibres of gluteus maximus, 5 cm below the posterior superior iliac spine and distally along the shaft of femur for 10 cm. The fascia over gluteus medius and maximus was incised and uncovering of vastus lateralis was performed. The gluteus maximus muscle was split along the direction of muscle fibres proximally. The sciatic nerve was identified and protected. The short external rotators were identified and cut as close to its insertion over the greater trochanter. Longitudinal or T shaped incision was made in the joint capsule and the head was posteriorly dislocated by internally rotating the femur along with some traction. Standard femoral neck osteotomy, acetabular preparation and sequential reaming followed. Sizing and trial was done before final placement of acetabular cup and polyethylene liner at 45°-50° inclination and 10° anteversion fixed with the appropriate size screws. After placing acetabular component, femoral canal was prepared with sequential broaching and appropriate size femoral stem was placed in 10° of femoral ante-version. Trial reduction was done to estimate the proper head-neck size and after satisfaction, the final size of head placed over the stem and stability of joint was checked after reduction. The wound was closed in layers over a drain (fig 1).

Postoperatively, the operated limb was kept in abduction with an abduction pillow in between the lower limbs. Drain was removed after 48 hours. Intravenous antibiotics were continued for 5 days. Static quadriceps exercises were started and patient was mobilized in bed from day one. Weight bearing and walking with support was started from 2nd day

postoperatively. Suture removal was done at 2 weeks. The contralateral hip was operated within 2 months of the primary THA. Patients were assessed functionally by Modified Harris hip scoring and radiologically by x rays for component placement and complications if any.

Fig 1. Intraoperative photograph of THA via postero-lateral approach showing incision (a), femoral neck osteotomy (b), acetabular reaming (c) and prosthesis placement



Results

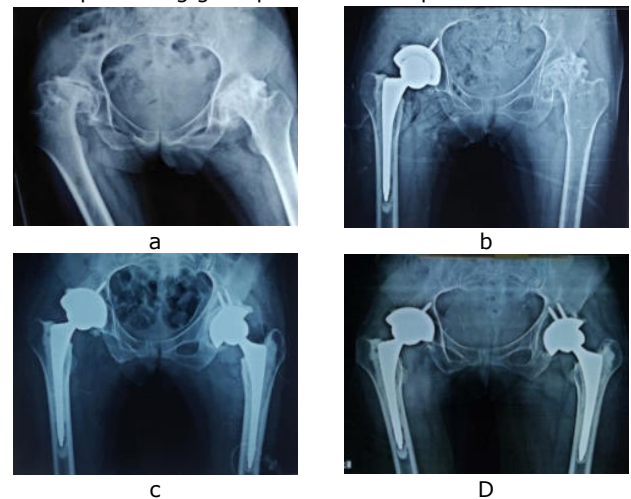
25 patients (50 hips) with mean age 34.92 years (range 19 to 59 years), who underwent bilateral total hip arthroplasty were included in the study. Out of these patients 20 (80%) were male and 5 (20%) were females. Most common cause of AVN was idiopathic as seen in 13 (52.0%) patients, followed by steroid induced as seen in 6 (24.0%) patients, in 4 (16.0%) patients it was alcohol induced and one each had AVN due to post traumatic fracture neck of femur and sickle cell disease. Three patients had associated co-morbidities in form of diabetes mellitus alone in one patient, hypertension alone in one and both diabetes and hypertension in one patient. In rest of the patients no co-morbidities were present. Mean blood loss was 350 ml in surgery.

The mean pre-operative HHS was 28.28 ± 2.97 and 26.40 ± 2.31 for right and left hip which improved significantly to 89.96 ± 3.32 and 88.08 ± 12.53 respectively after 6 months of bilateral THA suggesting excellent outcome.

Peri-prosthetic fracture and radiculopathy occurred in one patient each, leg length discrepancy (LLD) was seen in 2 cases

whereas in 3 cases unilateral dislocation was seen, all of which were treated accordingly. Hip dislocations were reduced on the same day under general anaesthesia. Maximum LLD was 2 cm which was treated by appropriate shoe raise. Wound Dehiscence and haematoma formation which was evident in 1 patient (4%) was treated by haematoma drainage and delayed suture removal. Peri-prosthetic fracture was found intra-operatively and thus was managed with encirclage wire and delayed weight bearing. One patient complained of anterior thigh pain which was managed conservatively and got resolved in 1 month.

Fig 2 – Antero-posterior X ray of pelvis preoperative (a), after right THA (b), after left THA (c) and 6 months followup showing good position of components.



Discussion

Total Hip Arthroplasty (THA) has been established as a reliable surgery of choice in relieving pain and dysfunction associated with hip arthritis [19]. The primary aim of THA is to provide a painless, stable and mobile hip to the patient. Selection of patients is of paramount importance while planning for total hip arthroplasty [20,21].

Alternative treatment for THA such as hip arthrodesis and resection arthroplasty, both give pain relief, but at the cost of mobility and stability respectively and so results in restriction of activities of daily living. Patients may also limp affecting hip biomechanics to such an extent that they will have low back pain and ipsilateral knee pain in long term. Resection hip arthroplasty leads to worse Harris Hip score, low satisfaction rate and poor

functional outcome. Also, the gait provided by each of these options has very high energy consumption. But the most important part is that both these procedures cannot be performed for bilateral involvements [22]. THA remains the only choice for bilateral hip arthritis.

The outcomes of bilateral THA are less explored. Hence we reviewed outcomes of bilateral THA in 25 patients (50 hips) with mean age of 34.9 years, operated by posterolateral approach and found significant improvement in mean pre-operative HHS of 28.28 ± 2.97 and 26.40 ± 2.31 for right and left hip to 89.96 ± 3.32 and 88.08 ± 12.53 respectively after 6 months of bilateral THA suggesting excellent outcome.

Goyal et al suggested cemented implants over uncemented implants as cemented implants are cheaper and provide painless and early full weight-bearing compared to uncemented implants [23]. Mäkelä et al compared the survival of cemented and uncemented hip replacement prosthesis in patients older than 55 years and concluded that cemented implants have better survival than uncemented implants [24]. Zimmerman et al concluded no statistically significant differences in clinical or functional outcomes between cemented and uncemented prostheses till 12 months' post-surgery [25]. We used both implants, with uncemented implants in 46 hips and cemented in 4 hips. The results were statistically insignificant on comparison of both the groups.

Oscar Skoog et al on studying the relations between hip surgical approaches and risk of reoperation due to dislocation found that

increased risk of dislocations is associated with using posterior Moore's approach compared with the direct lateral Harding's approach [26]. 2(8%) of our patients had posterior hip dislocations postoperatively within one month, but were managed on same day with closed reduction performed under general anaesthesia. The functional outcome didn't alter after the dislocation and was as good as other patients even at 6 months follow up. Other complications in our series were periprosthetic fracture and radiculopathy occurred in one patient each, leg length discrepancy (LLD) was seen in 2 cases, the incidence of which is acceptable and comparable to other studies.

In our study, we tried to reduce the influence of confounding variables by selecting a homogeneous and undiversified cohort of patients who received the similar type of uncemented total hip prosthesis and all were operated on by a single surgeon. The study is limited by shorter follow up and small number of patients.

Conclusion

Bilateral THA can be employed in patients with mid-term excellent to good functional outcome, high satisfaction rate and lower rate of complications. Patients returned to their work after surgery, who previously were unable to do so and started doing most of the activities of daily living without any difficulties. Longer follow-up and multicentric studies with larger sample size are necessary to establish confirmatory results.

References

1. Johansson HR, Zywiol MG, Marker DR, Jones LC, McGrath MS, Mont MA. Osteonecrosis is not a predictor of poor outcomes in primary total hip arthroplasty: a systematic literature review. *Int Orthop* 2011;35:465–73.
2. Kim YH, Choi Y, Kim JS. Cementless total hip arthroplasty with ceramic-on-ceramic bearing in patients younger than 45 years with femoral-head osteonecrosis. *Int Orthop* 2010;34:1123–7.
3. Bedard NA, Callaghan JJ, Liu SS, Greiner JJ, Klaassen AL, Johnston RC. Cementless THA for the treatment of Osteonecrosis at 10-year follow-up: have we improved compared to cemented THA? *J Arthroplasty* 2013;28:1192–9.
4. Kim YG, Kim SY, Park BC, Kim PT, Ihn JC, Kim ID. Uncemented Harris-Galante total hip arthroplasty in patients with osteonecrosis of the femoral head. A 10-16-year follow-up study. *Acta Orthop* 2005;76:42–8.

5. Han SI, Lee JH, Kim JW, Oh CW, Kim SY. Long-term durability of the CLS femoral prosthesis in patients with osteonecrosis of the femoral head. *J Arthroplasty* 2013;28:828-31.
6. Romagnoli S, Sacchetti S, Perazzo P, et al. Simultaneous bilateral total hip arthroplasties do not lead to a higher complication or allogeneic transfusion rates compared to unilateral procedures. *Int Orthop* 2013;37:2125-30.
7. Jones CA, Pohar S. Health-related quality of life after total joint arthroplasty: a scoping review. *Clin Geriatric Med* 2012;28:395-429.
8. Laursen JO, Husted H, Mossing NB. One-stage bilateral total hip arthroplasty a simultaneous procedure in 79 patients. *Acta Orthop Belg* 2000;66:265-71.
9. Sayeed SA, Johnson AJ, Jaffe DE, et al. Incidence of contralateral THA after index THA for osteoarthritis. *Clin Orthop Relat Res* 2012;470:535-40.
10. Goker B, Block JA. Risk of contralateral avascular necrosis (AVN) after total hip arthroplasty (THA) for non-traumatic AVN. *Rheumatol Int* 2006;26:215-9.
11. Learmonth ID, Young C, Rorabeck C. The operation of the century: total hip replacement. *Lancet* 2007;370:1508-19.
12. Masonis JL, Bourne RB. Surgical approach, abductor function, and total hip arthroplasty dislocation. *Clin Orthop Rel Res* 2002;405:46-53.
13. Inngul C, Blomfeldt R, Ponzer S, Enocson A. Cemented versus uncemented arthroplasty in patients with a displaced fracture of the femoral neck: A randomized controlled trial. *Bone Joint J* 2015;97: 1475-80.
14. Pennington M, Grieve R, Sekhon JS, Gregg P, Black N, et al. Cemented, cementless and hybrid prostheses for total hip replacement: a Cost-effectiveness analysis. *BMJ* 2013;27:346:f1026.
15. Thompson R, Kane RL, Gromala T, McLaughlin B, Flood S, et al. Complications and short-term outcomes associated with total hip arthroplasty in teaching and community hospitals. *J Arthroplasty* 2002;17:32-40.
16. Mizra SB, Dunlop DG, Panesar SS. Basic science considerations in primary total hip replacement arthroplasty. *Open Orthop J* 2010;4:169-80.
17. Angerame MR, Dennis DA. Surgical approaches for total hip arthroplasty. *Ann Joint* 2018;3:43.
18. Moretti VM, Post ZD. Surgical approaches for total hip arthroplasty. *Indian J Orthop* 2017;51:368-76.
19. Blemfeldt R, Tornkvist H, Eriksson K. A randomized controlled trial comparing bipolar hemiarthroplasty with the total hip replacement for displaced intracapsular fractures of the femoral neck in elderly patients. *J Bone Joint Surg Br* 2007;89:160-5.
20. Morshed S, Bozic KJ, Ries MD, Malchau H, Colford JM. Comparison of cemented and uncemented fixation in total replacement: A meta-analysis. *Acta Orthop* 2007;78:315-26.
21. Espehaug B, Furnes O, Engesaeter LB. 18 years of results with cemented primary hip prostheses in the Norwegian Arthroplasty Register. *Acta Orthop* 2009;80:402-12.
22. Wade R, Shah KA. Functional and Radiological outcome of Uncemented Total Hip Arthroplasty in Young Adults 5-year follow-up. *J Orthop.* 2020;18:237-9.
23. Goyal D, Bansal M, Lamoria R. Comparative study of functional outcome of cemented and uncemented total hip replacement. *J Orthop Traumatol Rehabil* 2018;10:23-8.
24. Mäkelä KT, Matilainen M, Pulkkinen P. Country wise results of total hip replacement. *Acta Orthop* 2014;85:107-16.
25. Zimmerma S, Hawkes WG, Hudson JI, Magaziner J, Hebel JR, et al. Outcomes of surgical management of total hip replacement in patients aged 65 years and older: Cemented versus cementless femoral components and lateral or anterolateral versus posterior anatomical approach. *J Orthop Res* 2014;20:182-91.
26. Potter HG, Foo L, Nestor B. What is the role of magnetic resonance imaging in the evaluation of total hip arthroplasty? *HSS J* 2005;1:89-93.