

Isolated Tuberculosis of Talus: A Case Report

Choudhari P, Champawat VS, Jain N

Investigation performed at Shri Aurobindo Medical College, Indore

Abstract

Case Report: Osteo-articular tuberculosis continues to be a major global pandemic, with its greatest impact in developing countries. Among osteo-articular tuberculosis, involvement of foot, particularly isolated involvement of the talus is an extremely rare event. We discuss such rare case of a 30-year-old male diagnosed with isolated tuberculosis of right talus treated with surgical debridement and curettage of the talus along with anti-tubercular therapy. After 12 months postoperative, the patient was able to carry out his daily activities without pain.

Keywords: Talus, Tuberculosis, Tubercular osteomyelitis, Osteoarticular tuberculosis

Address of correspondence:

Dr. Pradeep Choudhari,
Professor, Department of Orthopaedics,
Shri Aurobindo Medical College, Indore
Email – pchoudhari@rediffmail.com

How to cite this article:

Choudhari P, Champawat VS, Jain N. Isolated Tuberculosis of Talus: A Case Report. Ortho J MPC. 2019;25(2):82-84.
Available from:
<https://ojmpc.com/index.php/ojmpc/article/view/89>



Introduction

Tuberculosis is still a major health problem in many developing countries. Involvement of the musculo-skeletal system is seen only in 1-3% of all tuberculosis patients. There have been less than fifteen cases of tuberculosis of talus, described in the literature till date, to best of our knowledge [1]. The diagnosis of foot TB is challenging due to vague inconsistent symptomatology and presentation which closely resembles that of other more common disorders affecting this region. Delaying the accurate diagnosis in such cases can lead to late presentation of the disease with sequelae and spreading the disease to the adjacent joints thereby causing widespread destruction. We here report such a rare patient of isolated tuberculosis of the talus bone treated successfully.

Case Report

A 30 year old male presented in the outpatient department (OPD) at our institute with a 6 months history of swelling and pain in his right ankle joint. Constitutional symptoms like fever, weakness, and loss of weight were

absent but there was a positive history of loss of appetite. There was no history of preceding trauma. Pain was mild to moderate, localized to ankle joint more on anterior and medial aspect, gradually increasing and partially and temporary relieved on medication. The pain has now restricted his daily activity of living as well. There was history of complete vaccination done at childhood along with BCG (Bacille Calmette Guerin) vaccination done at birth for which the scar mark was present on left shoulder.

On examination, there was a healed sinus present on antero-medial aspect of right ankle joint. There was mild to moderate tenderness and swelling as well at the ankle. All the movements' dorsiflexion, plantarflexion, inversion and eversion were restricted at their extremes ends and slightly painful. There was no deformity present and toes were normal. Distal neurovascular status was also normal.

Haemogram and ESR were within normal limits. Mantoux test and X-ray chest were normal and sputum for AFB was negative. Human Immunodeficiency Virus (HIV), Hepatitis C Virus (HCV) and Hepatitis B

surfaces Antigens (HBs Ag) were found negative. Plain radiograph of the ankle showed an irregular circumscribed lytic lesion inside the affected part of the talus. MRI of the talus showed necrotic and lytic lesions over the posteromedial aspect with hypo-intense lesion in the T1 images (fig 1).

Patient was planned for surgical debridement and curettage. Under spinal anesthesia and in supine position, the talar lesion was approached via antero-medial approach. The lesion was approached after soft tissue dissection and opening the talus (fig 1). White cheesy material found inside the cavity. The lesion was curetted and debrided and cavity was filled with autologous bone grafts taken from iliac crest. The tissue curetted was sent for histological examination which showed pieces of fibro-collagenous tissue with large number of granulomas showing langhans giant cells, central necrosis and peripheral lymphocytes. Acid fast stain for Koch's bacillus was positive which confirmed tuberculosis of the talus.

A below knee POP cast was applied for one month along with 12 months of anti-tubercular chemotherapy which initially consisted of four drugs (Isoniazid, Rifampicin, Pyrazinamide and Ethambutol) for two months, three drugs (Isoniazid, Rifampicin, Pyrazinamide) for next six months and finally two drugs (Isoniazid, Rifampicin) for rest of four months. Physiotherapy was started one month post-surgery after cast removal and patient was followed up monthly. Partial weight bearing was allowed after one month post-operatively, followed by full weight bearing after two month post-operatively. The patient had no pain while walking and was able to perform daily activities without restrictions at 1 year follow up (fig 2).

Discussion

Tuberculosis still remains a major infection, causing death and disability worldwide [2]. Extra pulmonary involvement is noted in 23-30% of patients infected with TB, with only 1-3% having bone and joint disease. Thirty to fifty percent of patients with bone TB have

vertebral involvement [2]. Less frequently the appendicular skeleton, usually major weight-bearing joints of the lower extremity such as hip and knee are affected. The ankle and foot are rarely affected and account for only 1% of all TB infections [2,3].

In a report of 74 patients with foot or ankle TB, only one case of talus TB was reported by Dhillon et al [2]. Tuberculosis to talus, symptomatology is frequently led by an insidious onset of pain in the ankle with decreased range of motion and functional disability [4]. Vague and non-specific characteristics of the clinical picture explain the difficulty and delay in diagnosis, as observed by Anderson [3]. Blood investigations and radiographs are also nonspecific which can be normal at the early stage, as in our case. Subsequently signs of bone destruction and osteolysis appear [5].

The CT scan and Magnetic Resonance Imaging (MRI) have roles in making the early diagnosis in such unusual sites. CT scan reveals the extension of lesions and bony destruction. MRI shows bone destruction sites at a precocious stage [5]. Similar MRI findings can also be seen in osteochondritis dissecans of the talus. So confirmation is only by identifying the bacillus from the local lesion or by a histopathological study of the sequestra [4].

The aim of surgical treatment is two-fold. Firstly, to confirm the diagnosis by obtaining tissue for bacteriological and histological examination and secondly, to curette the lesion and decrease the bacterial load and fill the defect with bone graft or substitute. This treatment should always be complemented anti-tubercular chemotherapy with initially plaster cast immobilization, followed by physiotherapy [4]. The anti-tubercular regime is continued till 12-16 months which will results in favorable outcome despite the delay in diagnosis. Chemotherapy was instituted for a longer period primarily in consideration of the increased prevalence of tuberculosis in India. The prognosis in this disease and its resolution depends on early diagnosis and treatment.

Fig 1 – Pre-operative AP (a) & lateral (b) radiograph of ankle joint showing lytic lesion in talus which is hypointense on MRI T1 image (c). Intraoperative photo showing the lesion in talus (d)

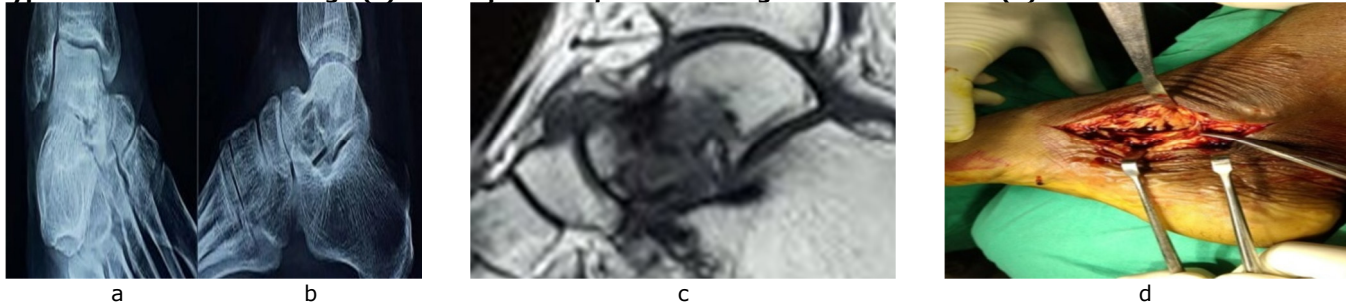
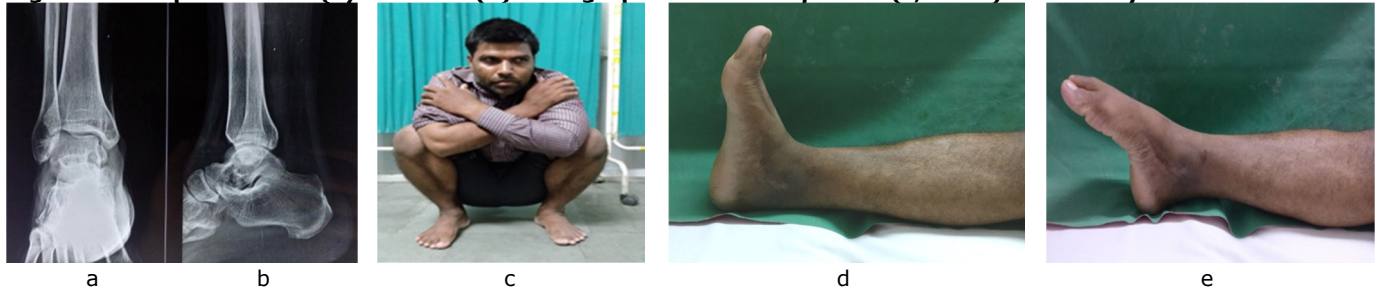

Fig 2 – Post-operative AP (a) & lateral (b) radiograph and clinical photos (c, d & e) after one year of treatment.



Conclusion

Talus tuberculosis is very rare entity and tuberculous osteitis of the talus should be considered in any long-standing inflammatory symptoms in the ankle. The symptoms are often vague, leading to late diagnosis. Rarity of the lesion and atypical presentation makes tuberculosis of the talus a difficult diagnosis on

clinical grounds. A normal ESR and negative Mantoux do not help either. This case has been reported to highlight the unusual skeletal manifestations of tuberculosis so as to prevent its misdiagnosis and delayed treatment. In patients with local involvement of the talus but favorable outcome can be achieved with surgical treatment by curettage and debridement and prompt chemotherapy.

References

1. Boussouga M, Tanane M, Bousselmame N, et al. Tuberculosis of the talus: a rare localization of Koch's bacillus. *Rev Chir Orthop Reparatrice Appar Mot.* 2002;88:522–525.
2. Dhillon MS, Nagi ON. Tuberculosis of the foot and ankle. *Clin Orthop Relat Res.* 2002;398:107–113.
3. Anderson JR, Ritchie AW, Scobie WG. Tuberculous osteitis of the talus. *Tubercle.* 1979;60:115–118.
4. Canale S, Beaty J. *Campbell's Operative Orthopaedics*, 11th edn. Philadelphia Pennsylvania: Mosby; 2008. Tuberculosis; pp. 758–758.
5. Hugosson C, Nyman RS, Brismar J. Imaging of tuberculosis. Peripheral osteoarticular and soft-tissue tuberculosis. *Acta radiol.* 1996;37:512–516.