

## Intradiscal Ozone Oxygen in Lumbar Disc Prolapse

Gupta V, Singh P K, Banode P, Khan S

*Investigation performed at Department of Orthopaedics Hiranandani Hospiatl, Mumbai, India*

### Abstract

**Background:** Lumbar disc herniation is one of common cause of hospitalization in current orthopaedics practice. There are great controversies whether to conserve or intervene for contained disc prolapsed. The purpose of current study to evaluate usefulness of intradiscal ozone infiltration for contained disc prolapsed.

**Methods:** Total 122 patients were treated with intradiscal ozone infiltration. All the patients who had contained disc prolapsed without neurological involvement were included in the study. Visual analogue scores and Mcnab scoring were used to evaluate results of the patients.

**Results:** The mean age of the patient was  $41.64 \pm 7.3$  and most of the patients were male who involved strenuous hard work. The mean pre-treatment VAS score was  $7.40 \pm 0.50$ , and at the end of follow up was  $3.40 \pm 1.25$ .

**Conclusion:** We can conclude that intradiscal oxygen-ozone is an alternative treatment modality for contained lumbar disk herniation.

**Keywords:** Intradiscal ozone; Disc prolapse; Contained disc

**Address for Correspondence:** Dr. Varun Gupta . Department of Orthopaedics, Dr. L H Hiranandani Hospital, Powai, Mumbai 400087.

**Email:** drvarun1234@gmail.com

**How to site this article:** Gupta V, Singh P K, Banode P, Khan S. Intradiscal ozone oxygen in lumbar disc prolapse. OrthopJMPC 2016;22(1): 15-19.

### Introduction

Low back pain is the most frequent medical cause of absence from work. It is now a major welfare and economic problem. In the era of industrialization, low back pain is extremely common with a prevalence ranging from 60-90% [1,2]. The appropriate treatment for lumbar sciatica and disc herniation is a challenge, particularly because the concept of a disc hernia represents only a simplification of the problem. There are many largely unknown or poorly understood factors involved in the pathophysiology of this disease. Clinically symptomatic contained disc poses lot of problem related to decision making of the procedure. These type of disc usually fall in

the grey area where surgeries are not absolutely indicated [3]. Intradiscal injection of oxygen-ozone have been proposed as a treatment for lumbar disc herniation [4,5]. Ozone consists of three oxygen atoms and is a colourless gas that is heavier than air with a pungent smell. Medical ozone is administered to the patient always in the form of a mixture of pure oxygen and pure ozone and in a certain concentration [6]. Oxygen zone therapy is minimally invasive treatment for lumbar disc herniation that exploits the biochemical properties of a gas mixture of oxygen and ozone. Disc herniation is the most common cause for spinal surgery and many clinicians employ epidural steroid injections with limited success. Intradiscal injection of ozone gas has been used as an

alternative to epidural steroids and surgical discectomy. Early results are positive but long-term data are limited [7]. The purpose of our study is to evaluate effectiveness of intradiscal oxygen ozone in treatment of lumbar disc herniation with respect to pain and function.

### Material & Methods

Present cohort study was done in our department between 2011 and 2013. Total 122 disc levels were treated with intradiscal ozone-oxygen mixture in 122 patients. Intradiscal ozone-oxygen was considered in those patient who had low back pain resistant to conservative management (drugs, physiotherapy, and others), lasting at least 3 months between ages of 18-65 years. All the patients who had low back pain with positive signs of nerve root involvement, with or without paraesthesia or hypoesthesia, with appropriate dermatome distribution were included. Radiological criterion for inclusion were a single level, broad based contained non extruded disc prolapse in line with the patient's clinical symptoms, without breach of posterior longitudinal ligament . However, the patients who showed advance degenerative changes in the disc, facet or in the body were excluded from the study. Patients with motor deficit were excluded from the study. All eligible patients were treated with single shot of intradiscal oxygen ozone under

fluoroscopy. Ethical committee approval was taken prior to research recruitment.

### Intradiscal Ozone Technique

The area was prepared with anti-septic solution and draped with sterile linen. The target disc was identified. After local anaesthesia (1% lidocaine) and needle tip position confirmation, 22G spinal needle was advanced by posterior para-median approach towards the disc at an angle of 45 degree under fluoroscopy control. When needle entered into the disc a specific resistance was felt. Before injection, it was confirmed that needle tip was into the nucleopulposus under the anteroposterior (AP) and lateral views to avoid injection into the outer annulus. Fluoroscope was positioned in true AP view and then fluoroscope was tilted cranially or caudally to abolish any double endplates for getting widest possible view of the disc (Figure 1). After that fluoroscope was rotated in axial plain so that ipsilateral facet joint divides width of vertebral body into two. Clinical outcome was assessed 48 hrs, 4 weeks, 12 weeks and 6 months after treatment. VAS score was evaluated at 48 hrs, 4 weeks, 12 weeks and 6 months whereas modified Macnab's method and SLR were applied only at the end of 6 months.

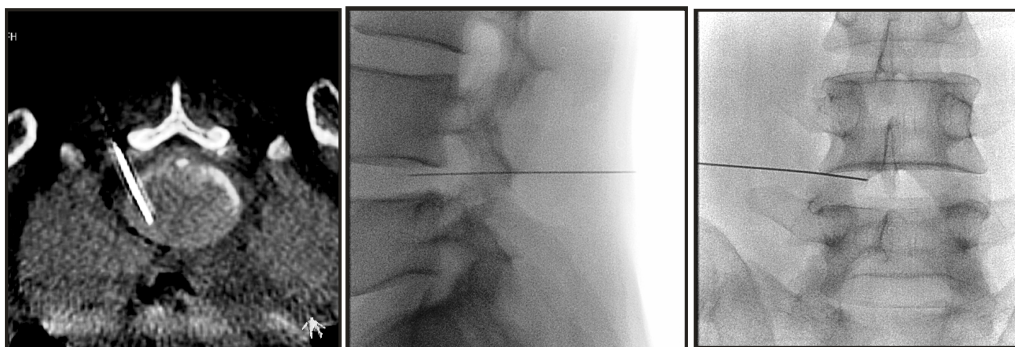


Figure 1: Fluoroscopic images showing needle in the intradiscal space

## Observation and Result

The mean age of patients with lumbar disc herniation in was  $41.64 \pm 7.3$  years. In our study, 68% patients were males and 32% patients were females (Table 1). Causative injury was lifting of heavy weight in 66% of patients and fall in 28% patients. 6% patients had no causative injury. 72% patients had L4-L5 disc disease, 28% had L3-L4 involvement, 12% had L5-S1 involved. None of the patient had L1-L2 involvement. The mean pre-treatment VAS score (Table 3) at day 0 was  $7.40 \pm 0.50$ , whereas on subsequent follow-up at 48hrs was  $5.44 \pm 1.04$ , at 4 weeks  $4.92 \pm 1.11$ , at 12 weeks

$4.12 \pm 1.23$  and 6th month  $3.40 \pm 1.25$ . By using students paired t test significant difference is found at day 0 and 48 hrs ( $t=8.92$ ,  $p=0.00$ ), 48 hrs and 4 weeks ( $t=2.98$ ,  $p=0.006$ ), at 4 weeks and 12 weeks ( $t=3.57$ ,  $p=0.000$ ), at 12 weeks and 6th month ( $t=3.16$ ,  $p=0.004$ ) (Table 4). The end result of the procedure was measured by Mcnab criteria which showed excellent result in 61 patients, good result in 43 patients and 18 patient showed poor result and subsequently surgery was done in 12 patients.

Age group(yrs)	Number f patients		$\chi^2$ -value	p-value
20-29	17		0.83	0.93 NS, $p>0.05$
30-39	43			
40-49	36			
50-59	19			
60-69	11			
70&Above	0			
Total	122			
Mean age	41.64	42.76		
SD	12	10.87		
Range	22-65	23-65		
Gender	Number of patients		Binomial	p-value
Male	83		0.5	0.24 NS, $p>0.05$
Female	39			
Total	122			
Occupation	Number of patients		$\chi^2$ -value	p-value
Light work	30		0.09	0.75 NS, $p>0.05$
Strenuous work	92			
Total	122			

Table 1: Demographic profile of the patients.

Level of disc	Patients %	$\chi^2$ -value	p-value
L1-L2	0(0%)	3.74	0.44 NS, $p>0.05$
L2-L3	1(4%)		
L3-L4	7(28%)		
L4-L5	18(72%)		
L5-S1	3(12%)		

Table 2: Causative injury and level of disc disease

	Mean	N	Std.Deviation	Std. Error Mean
Day 0	7.40	25	0.50	0.10
48hrs	5.44	25	1.04	0,20
4wks	4.92	25	1.11	0.22
12wks	4.12	25	1.23	0.24
6months	3.40	25	1.25	0.25

Table 3: Comparison of pain on VAS at day 0, 48 hrs, 4 weeks, 12 weeks and 6 months in Group A.

Paired Difference								
	Mean	Std.Deviation	Std.Error	95% Confidence interval of		t	df	p-value
				lower	upper			
Day 0-	1.96	1.09	0.21	1.50	2.41	8.92	24	0.000 S,
48hrs-	0.52	0.87	0.17	0.16	0.87	2.98	24	0.006 S,
4wks-	0.80	1.11	0.22	0.33	1.26	3.57	24	0.002 S,
12wks-	0.72	1.13	0.22	0.25	1.18	3.16	24	0.004 S,

Table 4: Descriptive statistics paired t test.

## Discussion

Non-invasive procedures, minimally invasive percutaneous injection and surgery represent the gamut of treatment available in the management of lumbar disc herniation. Minimally invasive treatments were developed to offer good clinical results combined with a well-tolerated, low cost procedure. Our study addressed the use of an oxygen-ozone mixture, the least invasive technique currently available for lumbar disc herniation. In our study the mean age of patients with lumbar disc herniation was 41.64 years. Spangfort's [8] series had an average age at presentation of 40.8 years. Average age at presentation in People, Griffith's [9] series was 42 years. Kerr's [10] studies of 100 patients had an average age of 40 years. Spangfort's(8) study showed that males constituted almost twice the number as females. That affection of males twice as often as females in their study may be attributed to the heavier nature of their work. Occupation of the patients is closely related to the disc pathology [11] and has been observed in 84% of patients were involved in occupations that caused physical stress. In our study occupation of 68% patients with lumbar disc herniation was strenuous work.

On analysing the VAS score significant difference was found when compared to their pre ozone infiltration status. "The overall estimated mean improvement was 3.9 for VAS and 25.5 for ODI. The estimated chance of showing improvement in the Modified MacNab scale was 79.7% [12]. In our study analysis of VAS score revealed significant difference in pre-treatment and subsequent post treatment when compared between pre-treatment and 48 hrs, 4 weeks, 12weeks and 6 months after the procedure (paired t-test p=0.00). In our study outcome was measured using modified Macnab criterion excellent in 50.3% patients and good in 35%patients. Treatment failure were noted in 14.7% patients and surgery was required in 10% patients. Gallucci M et al used Modified Macnab criteria as a tool to depict the outcome of treatment and found excellent results in 32% of patients [13]. In our study one patient had a complication of infective discitis. However the protocol for aseptic technique was followed strictly throughout the study [3]. Thomas Lehnert in his study evaluated 283 patients who received intra discal and periganglionic injection of ozone oxygen mixture under CT guidance and found that there is significant reduction in disk volume of lumbar herniated

disk [14]. Double blind randomized controlled trials should be conducted in order to conclude utility of Intradiscal Ozone techniques.

## Conclusion

## References

1. Brodke DS, Ritter SM (2005) Nonsurgical management of low back pain and lumbar disk degeneration. *Instr Course Lect* 54: 279-286.
2. Bressler HB, Keyes WJ, Rochon PA, Badley E (1999) The prevalence of low back pain in the elderly: a systematic review of the literature. *Spin* 24: 1813-1819.
3. Andreula CF, Simonetti L, de Santis F, Agati R, Ricci R, et al. (2003) Minimally Invasive Oxygen-Ozone Therapy for Lumbar Disk Herniation. *AJNR Am J Neuroradiol*: 996-1000.
4. Paradiso R, Alexandre A (2005) The different outcomes of patients with disc herniation treated either by microdiscectomy, or by intradiscal ozone injection. *Acta Neurochir Suppl* 92: 139-142.
5. Bonetti M, Fontana A, Cotticelli B, Volta GD, Guindani M, et al. (2005) Intraforaminal O(2)-O(3) versus periradicular steroidal infiltrations in lower back pain: randomized controlled study. *AJNR Am J Neuroradiol* 26: 996-1000.
6. Magalhaes FN, Dotta L, Sasse A, Teixeira MJ, Fonoff ET. Ozone therapy as a treatment for low back pain secondary to herniated disc: a systematic review and meta-analysis of randomized controlled trials. *Pain Physician* 2012; 15:115-E129
7. Buric J, Rigobello L, Hooper D. Five and Ten Year Follow-up on Intradiscal Ozone Injection for Disc Herniation. *International Journal of Spine Surgery*. 2014;8:17. doi:10.14444/1017.
8. Spangfort EV (1972) The lumbar disc herniation: A computer aided analysis of 2,504 operations. *Acta. Orthop. Scand (suppl)* 142: 5-95.
9. Pople IK, Griffith HB (1994) Prediction of an extruded fragment in lumbar disc patients from clinical presentations. *Spine* 19: 156-159.
10. Kerr RSC, Cadoux Hudson TA, Adam CBT (1988) The value of accurate clinical assessment in the surgical management of the lumbar disc protrusion. *J Neurol Neurosurg Psychiat* 51: 169-173.
11. O'Connell JEA (1951) Protrusions of the lumbar intervertebral discs A clinical review based on five hundred cases treated by excision of the protrusion. *J. Bone and Joint Surg* 33: 8-30.
12. Kieran Murphy, MD (2010) A Metanalysis of the Effectiveness and Safety of Ozone Treatments For Herniated Lumbar Discs. *Journal of Vascular and Interventional Radiology* 21: 534-548.
13. Gallucci M, Limbucci N, Barile LZ, Stavroulis E, Ricci A (2007) Sciatica Treatment with Intradiscal and Intraforaminal Injections of Steroid and Oxygen-Ozone versus Steroid Only. *Radiology* 242.
14. Lenhert T, Naquib NN, Wutzler S, Nour – Eldin NE, Bauer RW, Kerl JM et al. Analysis of disk volume before and after Ct guided intradiscal and periganglionic ozone – oxygen injection for the treatment of lumbar disc herniation. *J Vasc Interv Radiol* 2012; 23(11): 1430-1436

Through this study we can conclude that intradiscal oxygen-ozone can be useful treatment modality for contained lumbar disk herniation which has failed to respond to the conservative management in selected patient.