

A case report on nerve sheath tumour of median nerve at distal end radius damaging distal radius ulna joint

Girdhar S, Raheja P, Bajoria R S

Study performed at Department of Orthopaedics and Trauma Centre in J. A. Group of Hospitals, Gwalior MP

Abstract

PNSTs (Peripheral Nerve sheath tumors) are common tumors of hand present as solitary swelling along the course of nerve. However, Multiple swellings may be present along the course of nerve in patients of neurofibromatosis. The most common benign PNSTs are neurofibroma and schwannoma, which account for approximately 10% to 12% of all benign soft tissue neoplasms and may occur in upper and lower extremities. PNSTs generally presents with painless swelling.

In this paper, we present a 67-year-old female with swelling on her right wrist from last 6 months which was increasing gradually over the time for which she took treatment at various hospitals and was investigated. Patient was investigated radiographically and excisional biopsy was done and diagnosis was confirmed. On final follow up for last 6 months patient did not have any recurrence of swelling with complete movements at wrist joint.

Keywords: nerve sheath tumour, median nerve, distal radius ulna joint

Address of correspondence

Bajoria R.S., Professor,
Department Of Orthopedics,
Gajra Raja Medical College,
Gwalior (M.P.)

Email: rs_bajoria@yahoo.co.in

How to site this article

Girdhar S, Raheja P, Bajoria R S, A case report on nerve sheath tumor of median nerve at distal end radius damaging distal radius ulna joint. Ortho J MPC. 2022; 28 (2):88-90

Available from:
<https://ojmpc.com/index.php/ojmpc/article/view/165>



Introduction

Soft tissue tumours of bone are infrequent in Orthopaedics practice. Therefore peripheral nerve sheath tumours are uncommon and mostly mistaken for Ganglion of the wrist and have diagnostic and treatment challenges.¹ PNSTs (Peripheral Nerve sheath tumors) are tumors of hand present as solitary swelling along the course of nerve with incidence of 5% of all tumors of upper extremity.²

More common in females and have known to show association with Neurofibromatosis type 1.³ They usually grow slowly and appear as painless swellings for several years before diagnosed.⁴ Bony involvement is extremely rare, especially in the upper extremities⁵.

Although the diagnosis is established with imaging in most of the cases, the gold standard for diagnosis still remains histopathological examination⁶

Case Report

A 67-year-old female presented to our OPD with swelling on her right wrist from last 6 months which was increasing gradually, over the time for which took treatment at various hospitals. Regarding her family history, there were no reports of related systematic or neoplasm diseases. On clinical examination, swelling was firm, non-tender and no signs of inflammation were present and percussion over the mass produced a Tinel-like sensation along the median nerve. Neither motor weakness nor muscular atrophy was observed.

Other laboratory findings were normal. For the final excision, a longitudinal incision which was centred over the swelling was made, without releasing the transverse ligament of the carpal tunnel. The lesion was revealed in an eccentric position along the median nerve.

A marginal swelling excision with preservation of the median nerve was done after careful

surgical manipulations. After the complete excision of the mass, clear damage to the distal ulna and radius was seen. The defect of the bone and soft tissue was postoperatively protected with a forearm splint for six weeks and final diagnosis of PNST was made on the basis of Histological report. On final follow up for last 6 months patient did not have any recurrence of swelling with complete movements at wrist joint

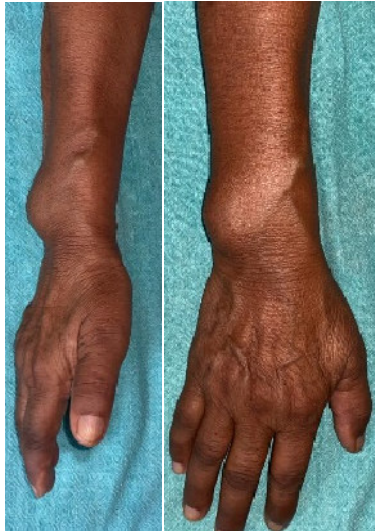

Figure 1 & 2 - Swelling present over the wrist MRI and FNAC was done at some private institution reporting it as Ganglion cyst. On radiographic imaging, X-Ray showed the characteristic pattern of a large soft tissue mass damaging distal radio ulnar joint was noted.

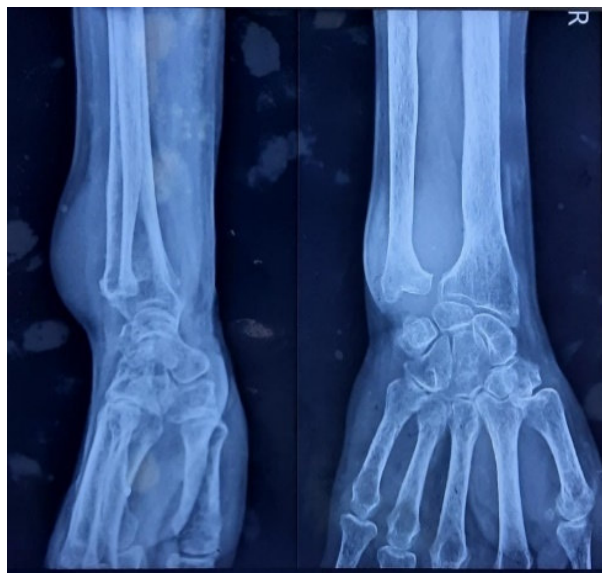

Figure 3 & 4- Xray suggestive of mass in between radius ulna destroying radius, Ulna and DRUJ anatomy

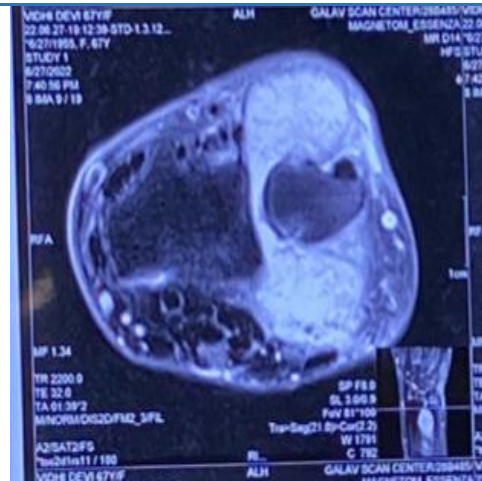

Figure 5

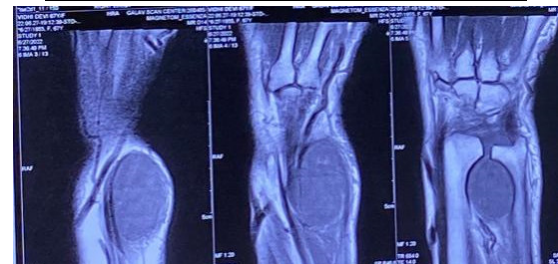
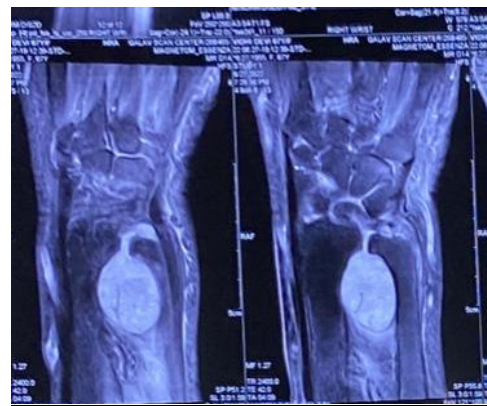

Figure 6 & 7 Well-defined PD FS hyperintense/T1 hypointense lesion noted in the distal forearm with widening of distal radioulnar joint. The lesion is seen the dorsal and volar aspect of distal forearm traversing in between distal radius and ulna. Th lesion is displacing the triangular fibrocartilaginous complex caudally.

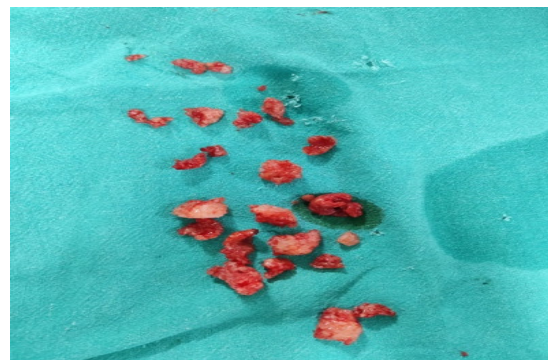


Figure 8- Intra operative Swelling Excision

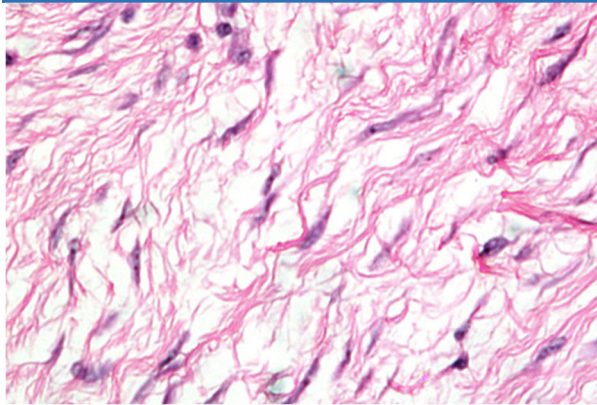


Figure 9-Histopathological slide showing tumour cells with elongated nuclei in collagen rich matrix

Discussion and Conclusion

Pathology behind Peripheral Nerve Sheath tumours of hand is not clear, most of these tumors are misdiagnosed as ganglion cyst.¹ Histopathological examination is the most important for diagnosis. Kubiena et al.⁷ showed that these lesions arise from the cells of the nerve sheath and engulf some nerve fascicles. However, bone destruction due to a benign NF is not so common. This presentation of bone damage is commonly seen in schwannomas, neuromas, and malignant tumors.⁸ The diagnosis of Peripheral nerve sheath tumor always remains a challenge and multiple differential diagnosis even after using MRI remains challenging and following tumors can be considered: benign solitary neoplasms such as lipomas, fibromas, xanthomas, ganglion tumors, mucous cysts, glomus tumors, giant cell tumors of the tendon sheath, vascular tumors, as well as post-traumatic neuromas, in addition to low-grade malignant neoplasms.⁹ A challenging step in the treatment is the complete tumor excision and the simultaneous preservation of nerve function. On the other hand, wide local dissection is difficult in patients who presents with large masses which infiltrate the surrounding soft tissue and bone.⁶

References

1. D.S.Louis and F.M.Hankin, "Benign nerve tumor of the upper extremity," *Bulletin of the New York Academy of Medicine*, vol. 61, no. 7, pp. 611–620, 1985.
2. World Health Organization. Lyon, France: International Agency for Research on Cancer; 2020. *Soft Tissue and Bone*

Tumours. WHO Classification of Tumours, 5th edition

3. The surgical management of symptomatic peripheral nerve sheath tumors. Levi AD, Ross AL, Cuartas E, Qadir R, Temple HT. *Neurosurgery*. 2010;66:833–840. [[PubMed](#)] [[Google Scholar](#)]
4. O. Ozdemir, C. Kurt, E. Coskunol, I. Calli, and M. H. Ozsoy, "Schwannomas of the hand and wrist: long-term results and review of the literature," *Journal of Orthopaedic Surgery*, vol. 13, no. 3, pp. 267–272, 2005.
5. Surgical management of neuromas of the hand and wrist. Regal S, Tang P. *J Am Acad Orthop Surg*. 2019;27:356–363. [[PubMed](#)] [[Google Scholar](#)] [[Ref list](#)]
6. The surgical management of symptomatic benign peripheral nerve sheath tumors of the neck and extremities: an experience of 442 cases. Desai KI. *Neurosurgery*. 2017;81:568–580. [[PubMed](#)] [[Google Scholar](#)] [[Ref list](#)]
7. Peripheral neural sheath tumors (PNST)--what a radiologist should know. Kubiena H, Entner T, Schmidt M, Frey M. *Eur J Radiol*. 2013;82:51–55. [[PubMed](#)] [[Google Scholar](#)] [[Ref list](#)]
8. Schwannoma: a rare benign tumor of soft tissues. Mankin HJ, Mankin KP. *Musculoskelet Surg*. 2014;98:95–99. [[PubMed](#)] [[Google Scholar](#)] [[Ref list](#)]
9. Benign nerve tumours of the hand (excluding wrist) Gosk J, Gutkowska O, Urban M, Martynkiewicz J, Bąk M, Ziółkowski P. *Arch Orthop Trauma Surg*. 2015;135:1763–1769. [[PubMed](#)] [[Google Scholar](#)] [[Ref list](#)]